

Original research article:

Histopathological study of lesions of nose, paranasal sinuses and nasopharynx

H. SHAH, S. SINGH* , B. P. BAVISKAR, S. D. DONGRE

Department of Pathology, Rural Medical College, Pravara Institute of Medical Sciences, Loni, Maharashtra, India

Corresponding author *

ABSTRACT:

The various lesions of the nose, paranasal sinuses and nasopharynx were subjected to histopathological evaluation over a period of 5 years (2010 to 2015) at the Department of Pathology, in a rural based hospital. Total 130 specimens were studied over the time of 5 years.

In the study, 84 cases were of Inflammatory and Non neoplastic lesions. Nasal polyps were the most common lesions with 77 (91.67%) cases. Among the all Nasal polyps, 77 cases, 20 (25.97%) cases were of Allergic polyp, 50 (64.93%) cases were of inflammatory polyp, while 7 (9.09%) cases were of Antrochoanal polyp.

In the study, 18 (13.84%) cases were of benign tumors, of which Capillary hemangioma was the commonest accounting for 7 (38.89%) cases and 23 (17.69%) cases were malignant tumors. The most common malignant tumor was Sinonasal Carcinoma accounting for 6 (26.09%) cases, followed by Squamous cell carcinoma, 5 (21.74%).

Keywords : Nose, Paranasal sinuses and Nasopharynx, Sinonasal mass

INTRODUCTION

We perceive our environment through our sensory receptors like nose. Lesions in upper respiratory tract are comparatively rare¹. Nasal cavity comprises of anterior and posterior part, paranasal sinuses and nasopharynx. Tumours arising or involving nasal cavity and paranasal sinuses were recognised in time of Hippocrates Nasopharynx is notably most difficult region to examine and there remains areas which may escape otolaryngologist's routine and more detail examination². A variety of neoplastic and non-neoplastic lesions involve nasal cavity, paranasal sinuses and nasopharynx. Clinically and radiologically benign and malignant lesions are hard to differentiate. Only definitive method is biopsy. Malignant lesions of nasal cavity and paranasal sinuses comprise about 1% cancers of human body³

while incidence of malignant neoplasm of nasopharynx is low in India 0.6%⁴, while high in China⁵. Polyps are tumour like lesions in nose which are projections of mucous membrane and develop in association with chronic rhinitis and sinusitis. Clinically polyps are smooth, shiny and present as movable swelling. It is quite impossible to distinguish clinically between simple nasal polyps, polypoidal lesions which are caused by specific granulomatous disease and polypoidal neoplasms⁶. Classification of tumours and tumour like lesions of nasal cavity, paranasal sinuses and nasopharynx –

1. Malformations
2. Inflammatory diseases
3. Benign tumours
4. Malignant tumours⁷

As most of the lesions are either inaccessible for fine needle aspiration cytology (FNAC) or FNAC is not recommended because of fear of brisk hemorrhage, histopathological study was carried out.

MATERIAL AND METHODS

The study was carried out at Rural Medical College and Pravara Rural Hospital, Loni, which is a tertiary care hospital in western Maharashtra, India. It is descriptive observational study. The Study was carried out from September 2010 to September 2015. All specimens of lesions in Nose, Paranasal sinuses and Nasopharynx received in the department of Pathology for histopathological findings were included.

Biopsies of specific sites along with Clinical data such as the age, sex, complaints and the record of other investigations were received and then processed in the laboratory by routine processing and stained by H&E.

RESULTS

The various lesions of the nose, paranasal sinuses and nasopharynx were subjected to histopathological evaluation over a period of 5 years (2010 to 2015) at the Department of Pathology, in a rural based hospital. Total 130 specimens were studied over the time of 5 years. Out of 130 specimens 5 specimens were Inadequate for opinion as the biopsy received was superficial or tiny.

Table No. I show distribution of All Nasal Lesions According to Histological Findings. The age wise distribution of all nasal lesions is given in **Chart I**.

The sex distribution is given in **Chart II**. The distribution of primary complaints presented by patients is given in **Chart III**.

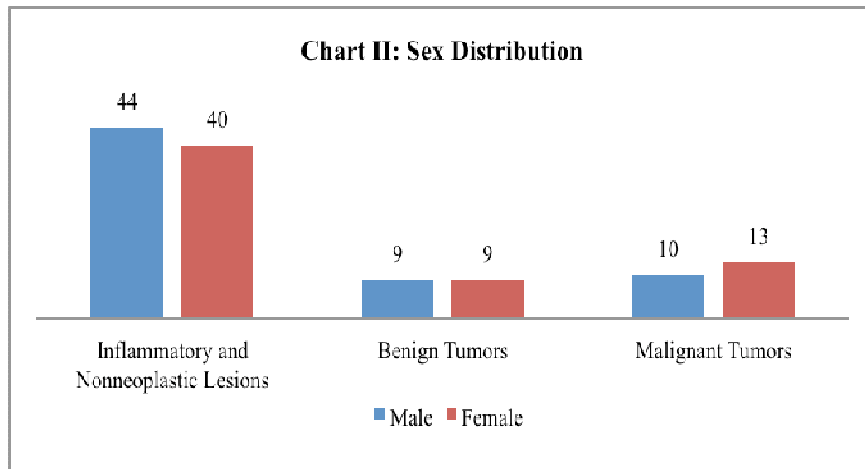
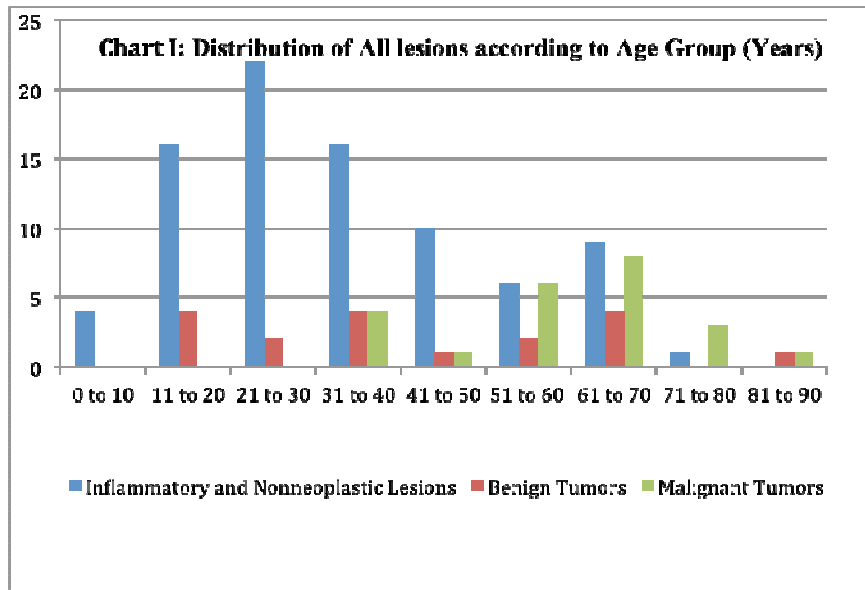
In the study, 84 cases were of Inflammatory and Non neoplastic lesions. Nasal polyps were the most common lesions with 77 (91.67%) cases, followed by the 2 cases (2.38%) each of Sinusitis and Intra dermal naevus. Rhinosporidiosis, Mucocele and Nasolabial cyst comprised of 1 (0.77%) case each respectively. Among the all Nasal polyps, 77 cases, 20 (25.97%) cases were of Allergic polyp, 50 (64.93%) cases were of Inflammatory polyp (**Figure I**), while 7 (9.09%) cases were of Antrochoanal polyp.

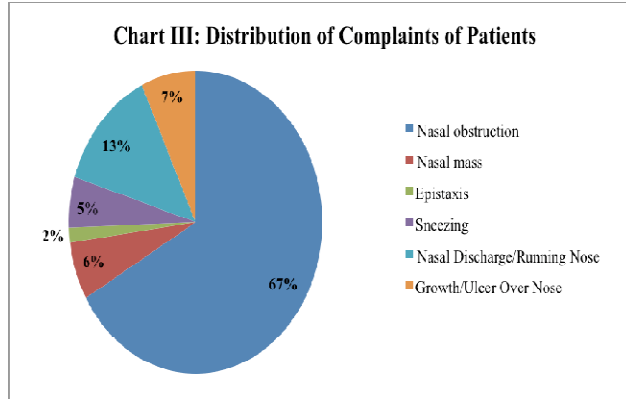
In the study, 18 (13.84%) cases were of benign tumors, of which Capillary hemangioma (**Figure II**) was the commonest accounting for 7 (38.89%) cases, followed by the Papilloma, Angiofibroma and Fibrous Dysplasia accounting for 3 (16.67%) cases each. There was 1 (5.56%) case of each of Trichoepithelioma and Osteoma.

In the study, 23 (17.69%) cases were malignant tumors. The most common malignant tumor was Sinonasal Carcinoma (**Figure III**) accounting for 6 (26.09%) cases, followed by Squamous cell carcinoma 5 (21.74%) (**Figure IV**). There were 3 (13.04%) cases of Basal cell carcinoma and 2 (8.70%) cases of Non Hodgkins Lymphoma, Adenoid cystic carcinoma and Nasopharyngeal carcinoma each. There was 1 (4.35%) case each of Keratoacanthoma, Malignant melanoma and Metastatic synovial sarcoma.

Table No. I: Distribution of All Nasal Lesions According to Histological Findings.

| Nature of Lesion | No. of Cases | Percentage of Cases |
|---|--------------|---------------------|
| Inflammatory and Non neoplastic lesions | 84 | 64.61% |
| Benign tumors | 18 | 13.84% |
| Malignant tumors | 23 | 17.69% |
| Inadequate Biopsies | 5 | 3.84% |
| Total | 130 | 100 % |





DISCUSSION:

In the present study, total number of cases was 130 and duration of study was 5 years. Average number of cases per year in present study was 26 cases / year. In other studies' of Dasgupta A⁸ with 17.4 cases/year and Kulkarni A⁹ with 16.71 cases/year and Tondon PL¹⁰ average number of cases per year were 10cases/year. This indicates low incidence of these cases for which biopsies are taken.

The age distribution in non neoplastic cases was between 1st to 8th decades, peak achieving in 2nd, 3rd and 4th decades. These findings correlated with the findings of Biswas G et al¹¹, Lathi A et al¹², and in the study of Zafar U et al¹³. In present study, age distribution in benign lesions was in 2nd to 9th decades of life with peak in 2nd, 4th and 7th decades (Chart I). These findings correlated with the findings of study of Swami KVN¹⁴, Khan N¹⁵, Lathi A et al¹² and Kulkarni A et al⁹. In present study, age distribution for malignant lesions were in the later decade of life starting from 4th decade till 9th decade, with a peak in 6th and 7th decades. These findings correlated with Biswas G et al¹¹, Panchal L et al¹⁶, Lathi A et al¹², Khan N et al¹⁵, Kulkarni A et al⁹ and Shah SN et al¹⁷

In present study, male to female ratio in inflammatory and non neoplastic cases was 1.1:1. This finding correlates with the finding of Lathi A et

al¹². In the study of Khan N et al¹⁵ and Zafar U et al¹³, male to female ratio was 1.7:1. In the present study, male to female ratio was 1:1 in benign lesions. These findings were correlating with the findings of Kulkarni A et al⁹, where male to female ratio was 1.6:1 and with findings of Lathi A et al¹², where male to female ratio was 1.7:1. In the study of Khan N et al¹⁵, male to female ratio was 3:1. In present study, male to female ratio in malignant cases found to be 1:1.3(Chart II).. Other studies, show males affected more than females by malignant lesions. In Khan N et al¹⁵, 2.3:1, in Lathi A et al¹², 3.3:1 and in Kulkarni A et al⁹, male to female ratio was 2:1

In the present study, most common presenting complaint was Nasal Obstruction (68.8%), followed by Nasal Discharge (13.6%), Nasal Mass (6.4%), Sneezing (5.6%) and Epistaxis (1.6%). In other studies by Biswas G et al¹¹, Panchal L et al¹⁶, Lathi A et al¹², Khan N et al¹⁵, Kulkarni A et al⁷¹ and Shah SN et al¹⁰⁰ Nasal Obstruction was the most common presenting complaint, followed by Nasal Discharge, Epistaxis and Nasal Mass (Chart III).

The most common lesions were non-neoplastic accounting for 84 (67.2%) cases, followed by malignant for 23 (18.4) cases and then benign for 18 (14.4%) cases. These finding correlated with the findings of Panchal L et al¹⁶, where 20 cases were

benign and 49 cases were malignant, Bist SS et al¹⁸, where 63 cases were non-neoplastic, 23 cases were benign and 24 cases were malignant and in the study of Nair S et al¹⁹, where 44 cases were non-neoplastic, 4 cases were benign and 5 cases were malignant. In the study of Eggston AA et al²⁰, Harrison DPH³, Panchal L et al¹⁶ and Bakari A et al²¹ non-neoplastic lesions were not studied. In the study of Eggston AA et al²⁰, Harrison DPH³, there were 60% benign-40% malignant and 67% benign-33% malignant lesions respectively.

The most common Non-neoplastic lesion in present study was Nasal Polyp comprising of 77 cases, followed by 2 cases each of Sinusitis and Intra-dermal Naevus which correlated with other studies of Dasgupta A et al⁸, Biswas G et al¹¹, Khan N et al¹⁵, Zafar U et al¹³, Lathi A et al¹², Bist SS et al¹⁸, Kulkarni A et al⁹, Kumari KMK et al²², where the commonest Non-neoplastic lesion was Nasal Polyp. In the study of Nair S et al¹⁹, cases of Sinusitis were more common than Polyp as the study was based on clinical findings. In the present study, inflammatory polyp (50 cases) was the most common among the all polyps, followed by the allergic polyp (20 cases). These findings were related with the other studies, like Bakari A et al²¹, where 35 cases were inflammatory polyp and 10 cases were Allergic polyp, Kumari KMK et al²², where 35 cases were Inflammatory polyp and 9 cases were Allergic polyp. In the study of Dasgupta A et al⁸ and Lathi A et al¹², Allergic polyps were more than Inflammatory polyps. Biswas G et al¹¹ and Nair S et al¹⁹, noted Antrochoanal polyps only. In the study of Dasgupta A et al⁸, Biswas G et al¹¹, Lathi A et al¹², Kulkarni A et al⁹ and Kumari KMK et al²², second most common lesion was Rhinosporidiosis. In present study, only one case of Rhinosporidiosis was found. No case of

Rhinoscleroma was identified in the present study as it is often missed clinically due to common complaints like purulent discharge and nasal obstruction.

In the present study, most common benign lesion was Capillary Hemangioma (7 cases), followed by 3 cases each of Papilloma, Angiofibroma and Fibrous Dysplasia. These findings correlated with Dasgupta A et al⁸, Lathi A et al¹² and Kulkarni A et al⁹. In the study of Khan et al¹⁵ and Kumari KMK et al²², Angiofibroma was the commonest finding, followed by Papilloma and Capillary Hemangioma.

In present study, most common malignant lesion found was sinonasal Carcinoma (6 cases), followed by the Squamous Cell Carcinoma (5 cases) and Basal Cell Carcinoma (3 cases). In other studies, mentioned above, Squamous Cell Carcinoma was commonest malignant tumor, followed by Nasopharyngeal Carcinoma, Adenoid Cystic Carcinoma, Sinonasal Carcinoma, Non Hodgkins lymphoma and Malignant Melanoma. Incidence of Sinonasal Carcinoma was high as compared to other studies because of high frequency of Tobacco and Bidi smokers and occupations related to wood industry. In present study, rare cases like Keratoacanthoma and Metastatic Synovial Sarcoma were noted.

CONCLUSION

Histopathological examination is simple, reliable and cost effective diagnostic procedure for the detection of various lesions of nasal cavity, nasopharynx and paranasal sinuses. Non-neoplastic lesions were more common than neoplastic lesions. Most common lesions were Nasal Polyps. Sinonasal Carcinoma was the most common malignant lesion observed. Male preponderance was observed, while most of the cases were presented in 2nd and 3rd decade of life. Nasal obstruction was the most common clinical presentation.

ACKNOWLEDGEMENTS

We are also thankful to ENT Department Pravara Rural Hospital & Pravara Medical Trust, Loni, and Maharashtra, India for providing permission and lending support to the project.

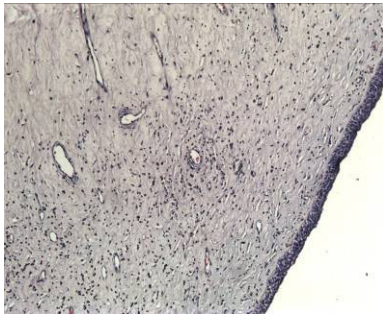


Figure I. Inflammatory Polyp H & E, X100

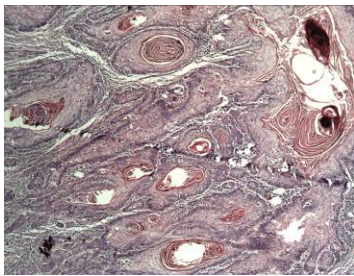


Figure IV. Squamous Cell Carcinoma, H & E, x 100

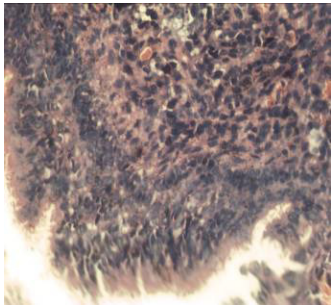


Figure III. Sinonasal Carcinoma, H & E, X 400

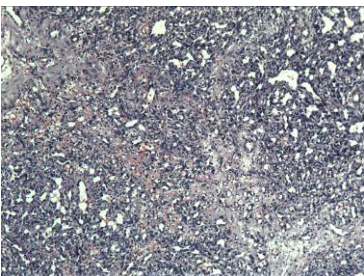


Figure II. Capillary Hemangioma H & E, X100

REFERENCES

1. Bosch ABV, Genaida F. Cancer Of The Nasal Cavity. *Cancer* 37 1979 ; P II : 1458-1463.
2. Dawes JBD, Harkine DG, Marshall NP, Von Miert, PG. Malignant Disease Of Nasopharynx. *J. Laryng Otol.* 1969 ; 85 : 211-238.
3. Harrison DPH. In : Scott Brown's Diseases Of The Ear, Nose And Throat. 3rd Edi. (3). Butterworths 1971 : 300.
4. Sawai MM, Talwalkar GV. Cancer Of Nasopharynx : A Review Of 1036 Cases Seen At T.M.H. Bombay India. *Ind J. Pathol Microbiol* 1983 May-Jun ; 20(2) : 89-96.
5. Chiang Chun Tze, Melvin G. Nasopharyngeal Cancer. *Surg. Clin. J Of North Amr* 1973 Feb ; 53 (1).
6. Bruce M W. Tumors Of Upper Respiratory Tract, Nasal Cavity, Paranasal Sinuses And Nasopharynx. In : Fletcher CDM. *Diagnostic Histopathology Of Tumours.* 3rd Edi. Churchill Livingstone 2007: 84.
7. Emani J, Baroody FM. Nasal polyposis. History of nasal polyposis. Springer Berlin Heidelberg 2010 : 1-7.
8. Dasgupta A, Ghosh RN, Mukherjee C. Nasal polyps-Histopathologic spectrum. *IJO & HNS* 1997 ; 49(1) : 32-37.
9. Kulkarni AM, Mudholkar VG, Acharya AS, Ramteke RV. Histopathological study of lesions of nose and paranasal sinuses. *IJO & HNS* 2012 ; 64(3) : 275-279.
10. Tondon PL, Gulati J, Mehta N. Histological study of polypoidal mass lesions in the nasal cavity. *Ind.J.Otol.*1971 ; 13 : 3-11.
11. Biswas G, Ghosh SK, Mukhopadhyay S, Bora H. A clinical study of nasopharyngeal masses. *IJO & HNC* 2002 ; 54(3) : 193-195.
12. Lathi A, Syed MMA, Kalakoti P, Qutub D, Kishve SP. Clinicopathological profile of sinonasal masses : a study from a tertiary care hospital of India. *Acta Otorhinolaryngologica Italica* 2011 ; 31 : 372-377.
13. Zafar U, Khan K, Afroz N, Hasan SA. Clinicopathological Study Of Non-Neoplastic Lesions Of Nasal Cavity And Paranasal Sinuses. *Indian J. of Pathol Microbiol* 2008 ; 51(1) : 26-29.
14. Swami KVN, Gowda BVC. A clinical study of benign tumors of nose and paranasal sinuses. *IJO & HNS* 2004 ; 56(4) : 265-268.
15. Khan N, Zafar U, Afroz N, Ahmad SS, Hasan SA. Masses of nasal cavity, paranasal sinuses and nasopharynx : A clinicopathological study. *IJO & HNS* 2006 ; 58(3) : 259-263.
16. Panchal L, Vaideeswar P, Kathpal D, Madiwale CV, Prabhat DP. Sino-nasal epithelial tumors. *J Postgrad Med* March 2005 ; 51(1) : 30-34.
17. Shah SN, Goswami Y. Study of Lesions of Nasal cavity, Nasopharynx and Paranasal Sinuses by Histological Examination. *Gujarat Medical Journal* 2012 ; 67(2) : 70-72.
18. Bist SS, Varshney S, Baunthiyal V, Bhagat S, Kusum A. Clinico-Pathological Profile of Sinonasal Masses: An experience in tertiary care hospital of Uttarakhand. *National Journal of Maxillofacial Surgery* 2012 ; 3(2) : 180-186.
19. Nair S, James E, Awasthi S, Nambiar S, Goyal S. A Review of the Clinicopathological and Radiological Features of Unilateral Nasal Mass. *Indian J. Of Otolaryngol, Head Neck Surg* 2013 ; 65 (2) : 199-204.
20. Eggston AA, Wolff DD. *Histopathology of ear, nose and throat.* Baltimore, The Williams & Wilkins Co. 1947 : 816.
21. Bakari A, Afolabi OA, Adoga AA, Kodiya AM, Ahmad BM. Clinico-pathological profile of sinonasal masses: an experience in national ear care center Kaduna, Nigeria. *BMC Research Notes* 2010 ; 3 : 186.
22. Kalpana Kumari MK, Mahadeva KC. Polypoidal Lesion In Nasal Cavity. *J.Clinical And Diagnostic Research* 2013 ; 7(6) : 1040-1042.